

Treatment of Vaginal Papillary Adenocarcinoma in a DES-exposed Woman with a Chronic Vaginal Cyst

Matt McCurdy, MD, PhD and Nicolas Zouain, MD, University of North Dakota School of Medicine and Health Sciences



Learning Objectives

- Vaginal papillary serous adenocarcinoma is a rare malignancy.
- Patients with vaginal adenomas need surveillance for malignancy.
- DES exposure in utero is known to increase the risk of vaginal clear cell tumors < 30 years old¹. This case suggests that DES exposure may also increase the risk of non-clear cell vaginal tumors in daughters as they age.
- Advances in radiotherapy are improving outcomes while reducing treatment side effects.
 - High dose rate brachytherapy with an intracavitary mould applicator eliminated the need for radical surgery in this patient.
 - The patient experienced only limited side effects.
 - The chemotherapy agents used acted to sensitize the tumor cells to the radiation.

Case Report

History

A 56 year-old woman presented with postmenopausal bleeding. She had never taken hormone replacement therapy. She denied dysmenorrhea, change in weight, or emotional stress. She had not had any bleeding since menopause 6 years ago. Of note, she had a vaginal cyst present for 30 years, requiring intermittent aspiration.

Physical Exam

On pelvic exam, external genitalia appeared normal. On vaginal exam, a cystic structure 3 to 4 cm in diameter with smooth-surfaced was present with oozing blood. No tenderness could be elicited. No other masses were palpable.

Work-up

- Pap smear – negative
- Vaginal ultrasound – 2.4 cm cyst in the anterior vaginal wall.
- Biopsy of vaginal cyst – high grade papular serous adenocarcinoma
- PET scan – large, slightly irregular, lobulated hypermetabolic mass near the midline. Activity in the lymph nodes in the left groin and right sacral area.
- Stage IIIC by the AJCC staging system, T2 N1 M0 and stage II by the FIGO staging system

Papillary Serous Adenocarcinoma

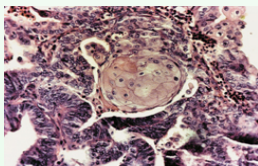


Figure 1 – Papillary serous adenocarcinoma of the vagina (hematoxylin-eosin stain).

Papillary serous adenocarcinoma² has a poor prognosis. It is distinguished from clear cell carcinoma by the absence of a clear cell component. Its appearance is suggestive of ovarian carcinoma, and the tumor cells are supported on thin, fibrovascular cores forming delicate papillary fronds (see adjacent Figure 1).

Treatment

HDR brachytherapy was employed to deliver 45 Gy to the tumor surface. The patient then received 6 weeks of concomitant chemoradiation, consisting of weekly cisplatin and intensity modulated radiotherapy to a total dose of 50 Gy in 25 fractions to the tumor and 45 Gy in 25 fractions to the pelvic and inguinal lymph nodes. An electron boost to the left inguinal lymph nodes was used to give an additional dose of 30 Gy in 15 fractions. Figure 2 shows the dose, in Gray, of radiation to each organ in the treatment field by volume of tissue.




Figure 2 – Dose Volume Histogram. Blue = Clinical target volume. Red = Gross tumor volume. Brown = Rectum. Yellow = Bladder. Purple = Right femur. Sky blue = Left femur. Orange = Bowel.

High Dose Rate Brachytherapy



Figure 3 – Intracavitary Mould Applicator

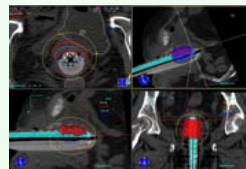


Figure 4 – HDR Brachytherapy Dose Distribution.

External Beam Radiation

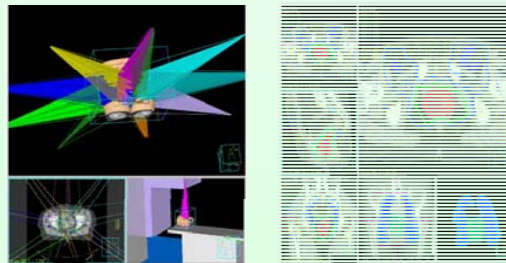


Figure 5 – Treatment beams in the external beam radiation treatment plan. Multiple beam arrangements allow a higher dose delivered to the tumor bed while sparing normal tissue. The linear accelerator is shown in the bottom right.

Figure 6 – Cross-sectional view of the radiation isodose distribution.

Discussion

Asymptomatic Vaginal Cysts

To our knowledge, this is the first case report of an adenocarcinoma arising from an epidermal inclusion cyst. The possibility of malignant transformation should be considered and careful follow-up is warranted even in cases of asymptomatic vaginal cysts.

DES exposure

This case describes a papillary adenocarcinoma in a patient of a possible DES-exposed mother. Non-clear cell adenocarcinomas in two older women with DES exposure have been reported, suggesting an association between DES and non-clear cell adenocarcinoma in older women³.

High Dose Rate Brachytherapy

HDR brachytherapy is an appealing treatment option for vaginal adenocarcinoma. Vaginal HDR brachytherapy has very low incidence of side effects⁴ and considering the short overall treatment time, it appears to be cost beneficial.

References

1. Mittendorf, R. Teratogen update: Carcinogenesis and teratogenesis associated with exposure to diethylstilbestrol (DES) in utero. *Teratology*. 1995 Jun;51(6): 435-45.
2. Riva C, Fabbri A, Facco C, Tibiletti MG, Guglielmin P, Capella C. Primary serous papillary adenocarcinoma of the vagina: a case report. *Int J Gynecol Pathol*. 1997 Jul;16(3):286-90.
3. DeMars LR, Van Le L, Huang I, Fowler WC. Primary non-clear-cell adenocarcinomas of the vagina in older DES-exposed women. *Gynecol Oncol*. 1995 Sep;58(3):389-92.
4. Atahan et al. Vaginal high dose rate brachytherapy alone in patients with intermediate- to high-risk stage I endometrial carcinoma after radical surgery. *Int J Gynecol Cancer*. 2008 Feb 15 (epub online).

Acknowledgements

The first author appreciates the guidance of Dr. Zouain and assistance of Mr. Justin Hayes in obtaining images of the treatment plan.